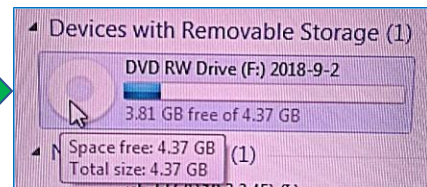
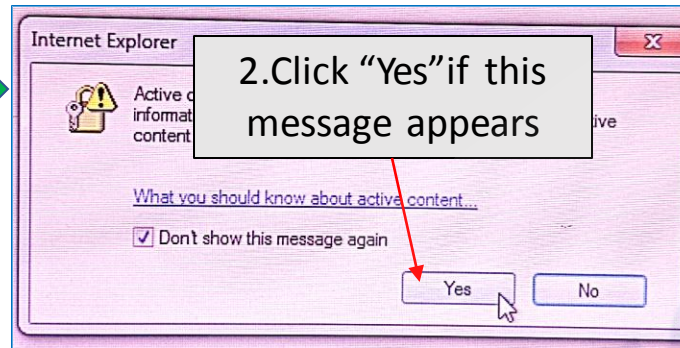


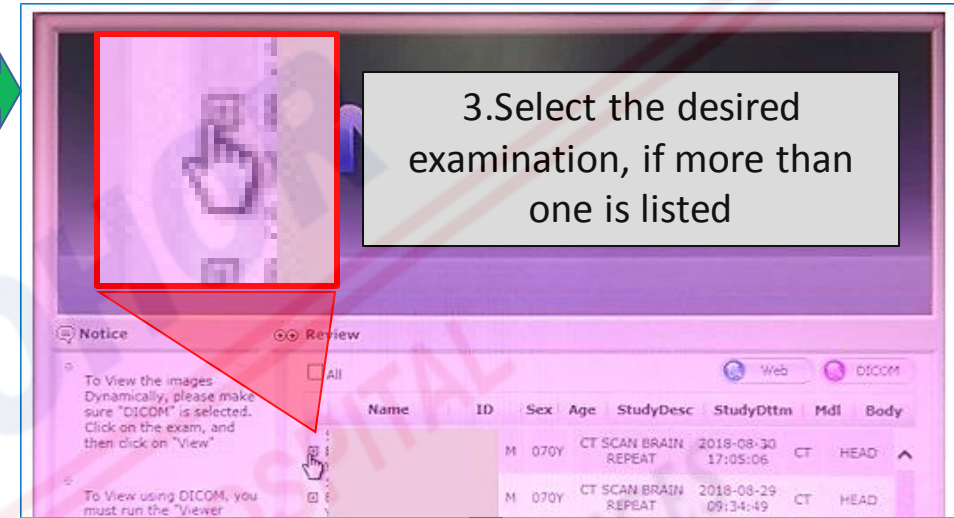
VIEWING IMAGES AND REPORTS



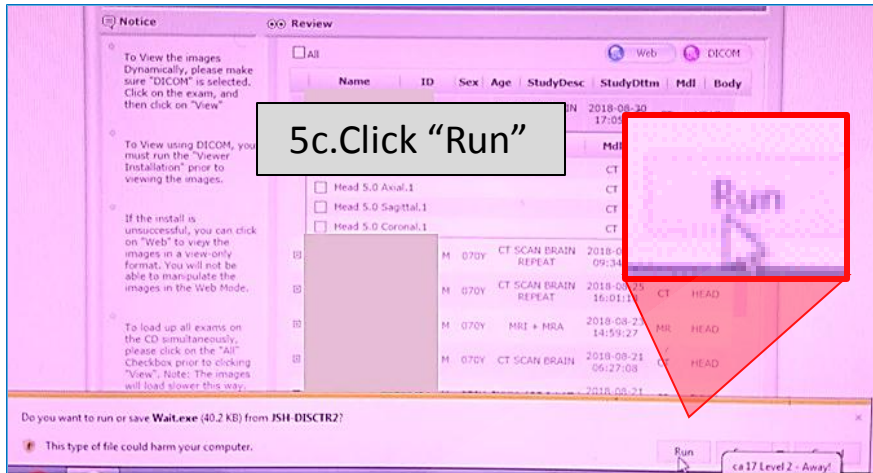
1. Load the disc and select if necessary



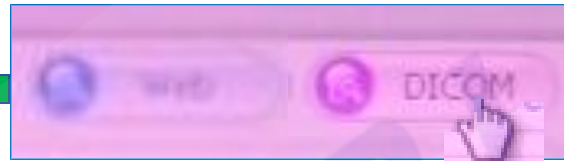
2. Click "Yes" if this message appears



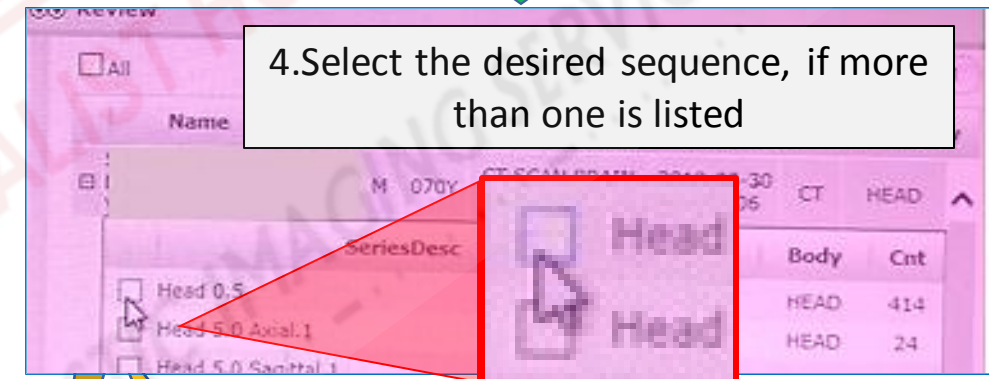
3. Select the desired examination, if more than one is listed



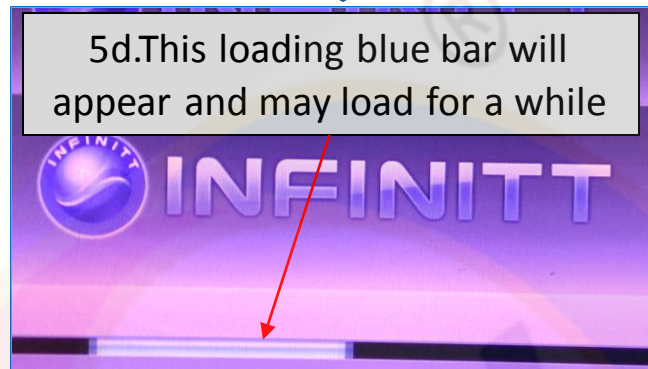
5c. Click "Run"



5b. Click on "DICOM" if you want to view the report as well as manipulate the images




4. Select the desired sequence, if more than one is listed



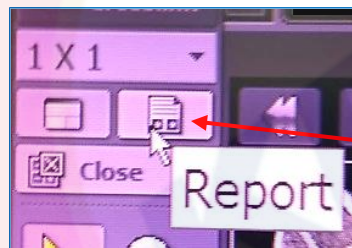
5d. This loading blue bar will appear and may load for a while

5e. Click on the desired scan, the bar will turn blue



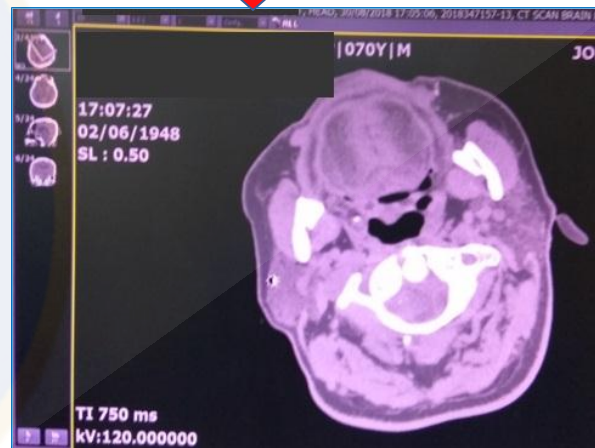
Sex	Birth Date	Study Date	Modality
M	19-480602	30/08/2018 17:05:06	C
M	19-480602	29/08/2018 09:34:49	C

5a. Click on "Web" if you only want to quickly view simple images

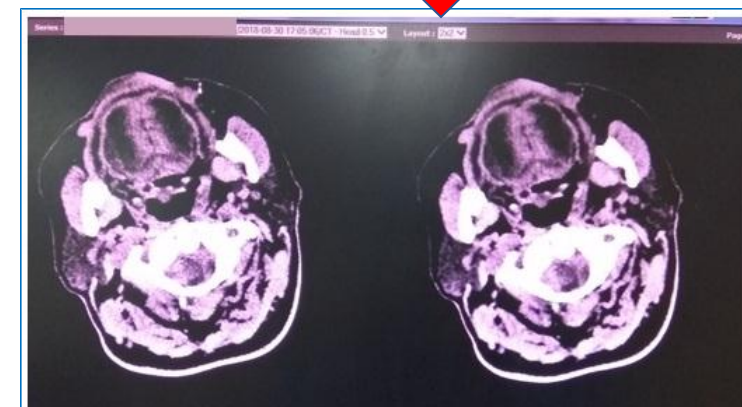
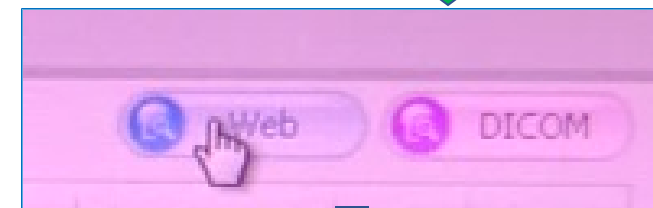
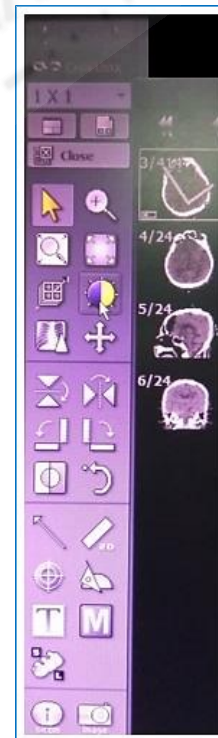


Click on this icon to view the report

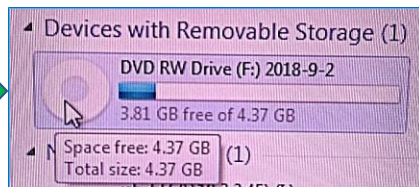
Plain CT Brain
 Indication: Bilateral chronic subdural haemorrhage post drainage
 Findings:
 Comparison made with previous CT dated 29/8/2018. Right frontal burrhole noted. Drainage catheter seen in the right frontal region. Previously seen right frontal-temporal-parietal subdural effusion is almost no longer seen. There is a large right fronto-pneumocephalus noted. The left frontal-parietal left acute on subacute subdural bleed large compared to before measuring 0.9cm in maximal thickness (previously 0.6cm). There are now multiple air pockets seen within the left subdural space.



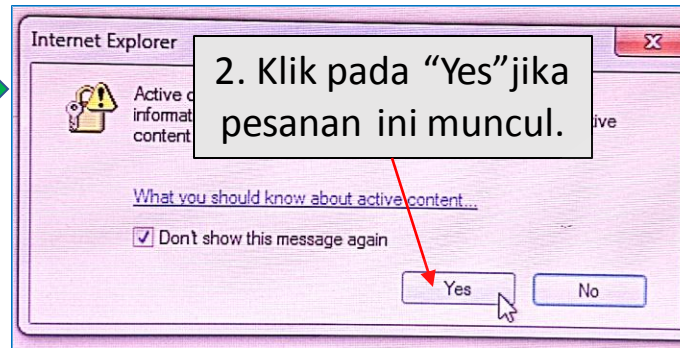
Click on these icons to adjust the images



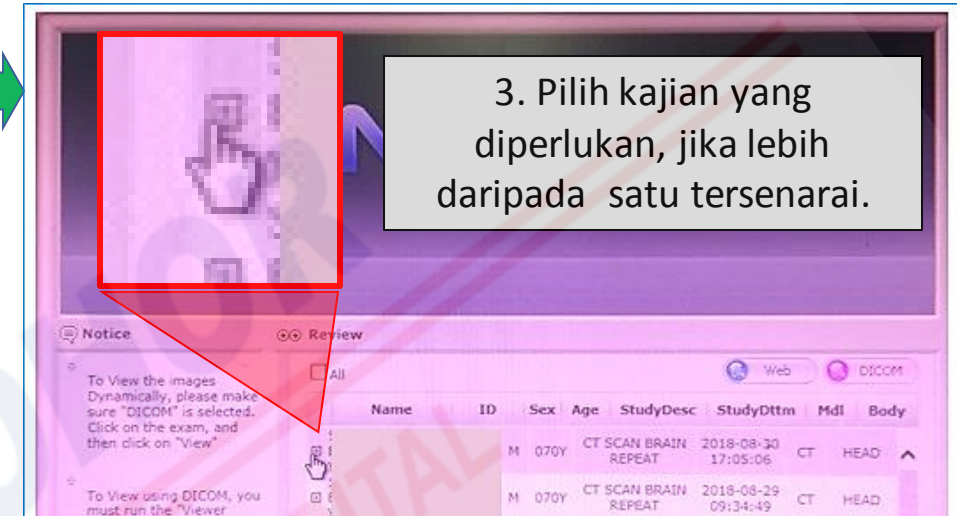
MELIHAT IMEJ DAN LAPORAN



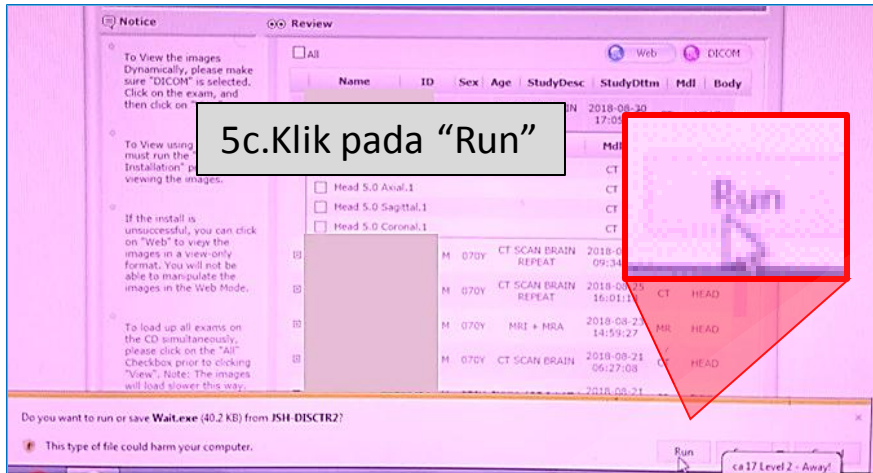
1. Masukkan cakera ke dalam pemacu dan "pilih" jika perlu.




2. Klik pada "Yes" jika pesanan ini muncul.



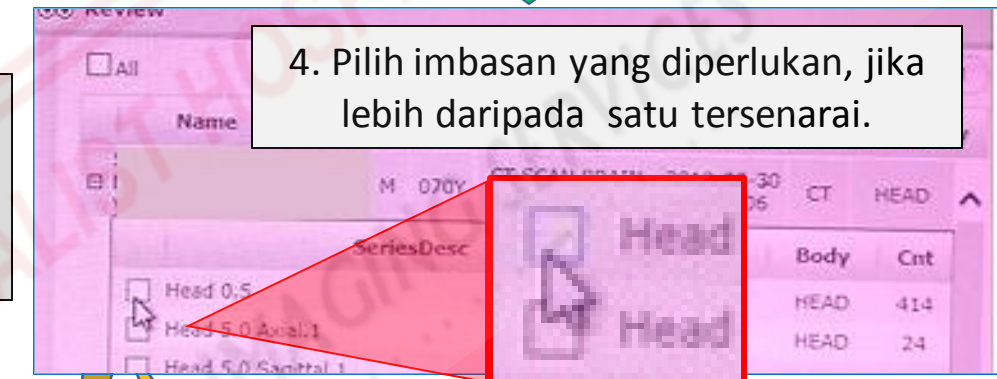
3. Pilih kajian yang diperlukan, jika lebih daripada satu tersenarai.



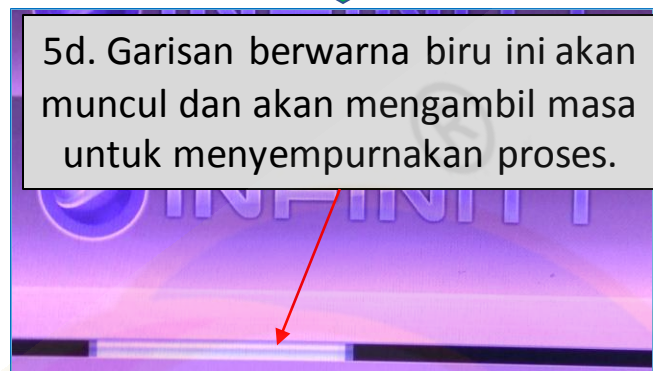
5c. Klik pada "Run"



5b. Klik pada "DICOM" jika ingin melihat laporan dan mengolah imej




4. Pilih imbasan yang diperlukan, jika lebih daripada satu tersenarai.



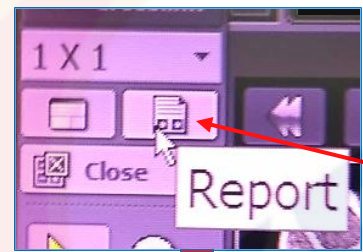
5d. Garisan berwarna biru ini akan muncul dan akan mengambil masa untuk menyempurnakan proses.

5e. Klik pada imbasan yang diperlukan, yang akan bertukar warna kepada biru.



Sex	Birth Date	Study Date	Modality
M	19480602	30/08/2018 17:05:06	C
M	19480602	29/08/2018 09:34:49	C

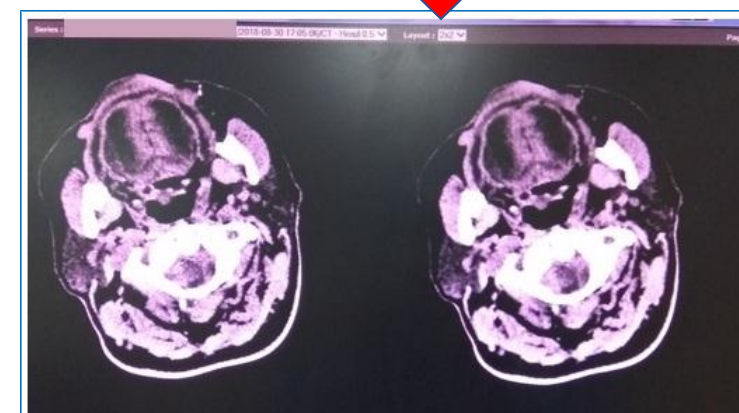
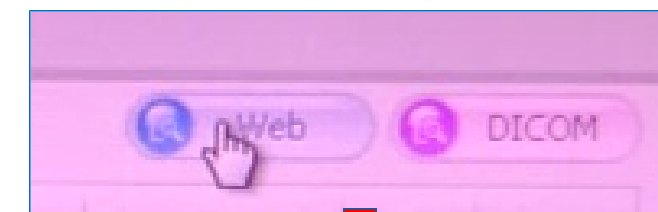
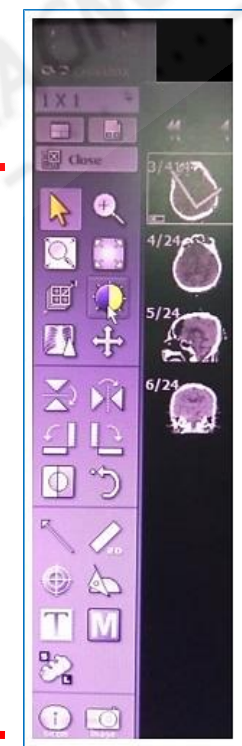
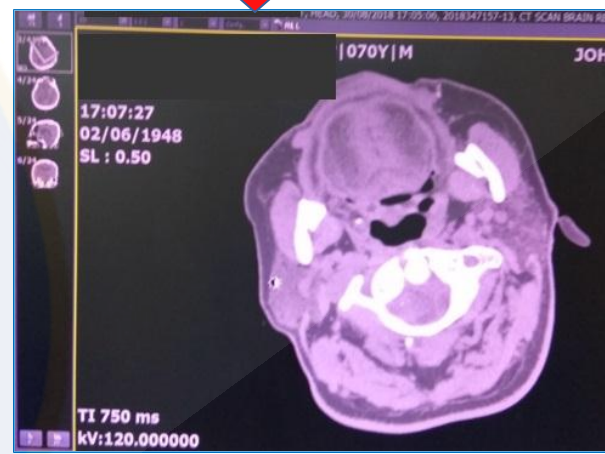
5a. Klik pada "Web" jika hanya ingin melihat imej ringkas, tanpa laporan



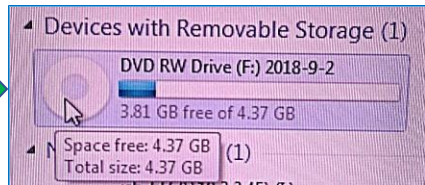
Klik pada ikon ini untuk melihat laporan

Plain CT Brain
Indication: Bilateral chronic subdural haemorrhage post drainage
Findings:
Comparison made with previous CT dated 29/8/2018. Right frontal burrhole noted. Drainage catheter seen in the right frontal region. Previously seen right frontal-temporal-parietal subdural effusion is almost no longer seen. There is a large right fronto-pneumocephalus noted. The left frontal-parietal left acute on subacute subdural bleed large compared to before measuring 0.9cm in maximal thickness (previously 0.6cm). There are now multiple air pockets seen within the left subdural space.

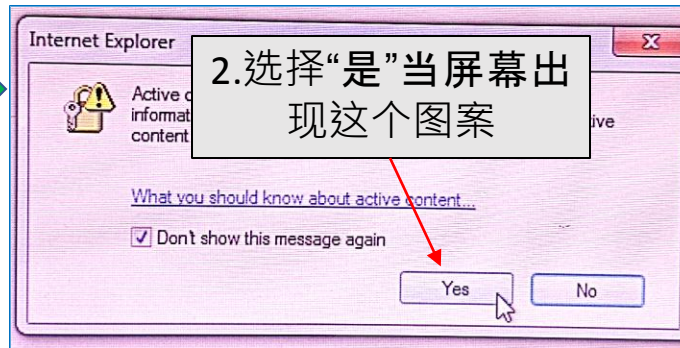Klik pada ikon ikon ini untuk mengolah imej



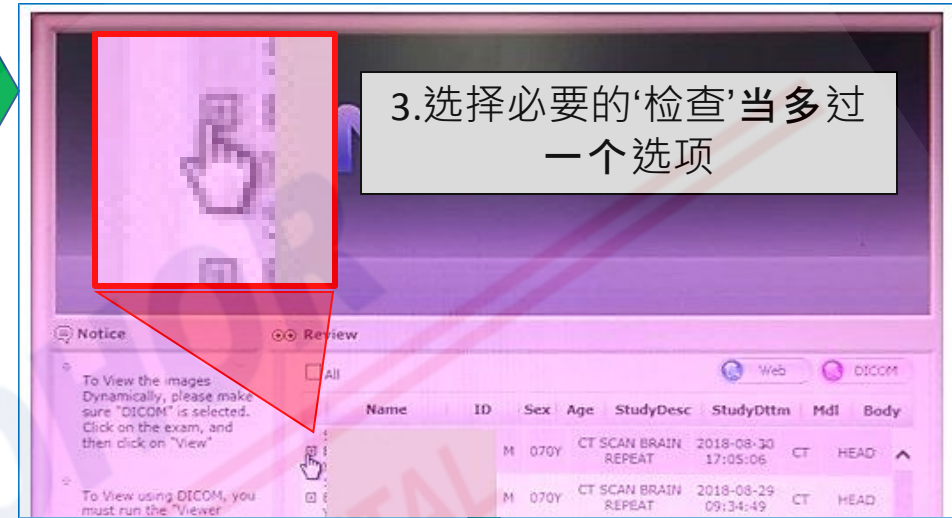
查看图像和报告



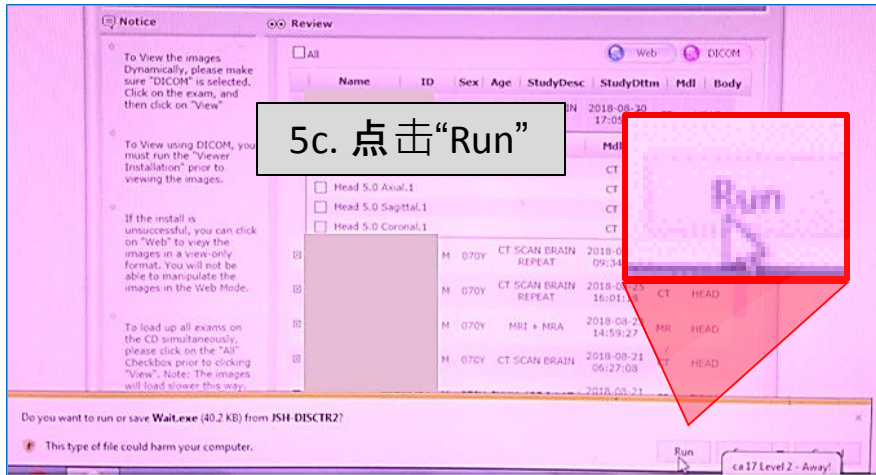
1. 读取光碟，并在必要时挑选



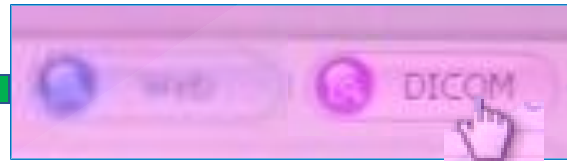2. 选择“是”当屏幕出现这个图案



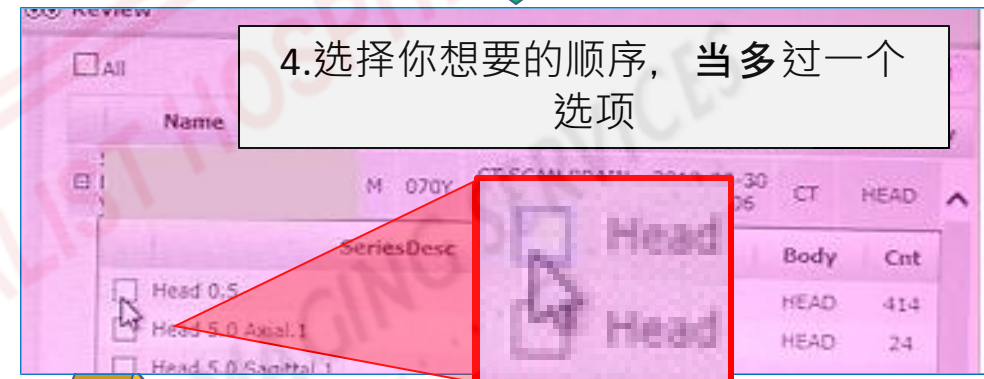
3. 选择必要的‘检查’当多过一个选项



5c. 点击“Run”



5b. 如果您想看报告和调整图案，请点击“DICOM”




4. 选择你想要的顺序，当多过一个选项




5d. 蓝色的等候条状将会出现，请等候片刻

5e. 点击您想要的扫描，蓝色的条状会出现



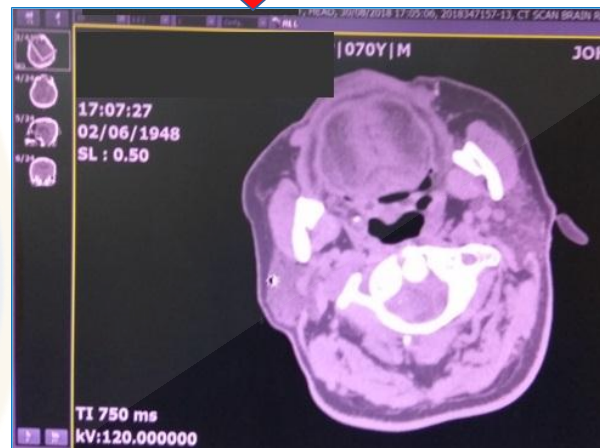
5a. 如果你想快速看到图案，请点击“web”



请点击这图像，如果您想显示你的报告

Plain CT Brain
Indication: Bilateral chronic subdural haemorrhage post drainage
Findings:
Comparison made with previous CT dated 29/8/2018. Right frontal burrhole noted. Drainage catheter seen in the right frontal region. Previously seen right frontal-temporal-parietal subdural effusion is almost no longer seen. There is a large right fronto-pneumocephalus noted. The left frontal-parietal left acute on subacute subdural bleed large compared to before measuring 0.9cm in maximal thickness (previously 0.6cm). There are now multiple air pockets seen within the left subdural space.

Sex	Birth Date	Study Date	Modality
M	19-480602	30/08/2018 17:05:06	C
M	19-480602	29/08/2018 09:34:49	C



请点击这些选项来调整图像

